

## The Intervention of Trunk Posture on Fowler 30° to Reduce Shortness of Breath in Congestive Heart Failure Patients: Case Study

Anggi Jamiyanti<sup>1\*</sup>, Sarah Arnika Simatupang<sup>1</sup>, Trias Eka Nurlela<sup>1</sup>, Eka Afrima Sari<sup>1</sup>,  
Yusshy Kurnia Herliani<sup>1</sup>, Ramdani<sup>2</sup>

<sup>1</sup>Departement of Medical Surgical Nursing, Faculty of Nursing, Universitas Padjadjaran, Bandung, Indonesia

<sup>2</sup>Rumah Sakit Umum Daerah dr. Slamet Garut, Garut, Indonesia

\*Corresponding email: [anggi19001@mail.unpad.ac.id](mailto:anggi19001@mail.unpad.ac.id)

### ARTICLE INFO

#### How to Cite:

Jamiyanti A., Simatupang, S.A., Nurlela T.E., Sari, E.A., Herliani, Y.K., & Ramdani, R. (2022). Intervention of Trunk Posture on Fowler 30° to Reduce Shortness of Breath in Congestive Heart Failure Patients: Case Study. *Jurnal Pendidikan Keperawatan Indonesia*, 8(2), p. 107–112

#### DOI:

10.17509/jpki.v8i2.50539

#### Article History:

**Received:**  
October 10, 2022

**Revised:**  
December 02, 2022

**Accepted:**  
December 27, 2022

**Published:**  
December 31, 2022

Copyright©2022 by authors, all rights reserved. Authors agree that this article remains permanently open access under the terms of the Creative Commons Attribution-ShareAlike 4.0 International License

### ABSTRACT

**Introduction:** Shortness of breath in patients with congestive heart failure is caused by impaired lung function due to pulmonary. One of the efforts that can be made to overcome shortness of breath and improve oxygenation status is to change the position of the trunk posture in fowler 30°. **Objective:** This case study was conducted to analyze the application of the 30° trunk posture in the fowler position in patients with congestive heart failure who experience shortness of breath. **Method:** The research used a case study of patients with congestive heart failure who experience shortness of breath. **Result:** After giving a 30° trunk posture in the fowler position for three days of treatment, there was a change of blood pressure, pulse rate, respiration, and oxygen saturation of the patient. **Conclusion:** The position of the trunk in fowler posture 30° can reduce shortness of breath in patients with congestive heart failure.

**Keywords:** Congestive Heart Failure, Shortness of Breath, Trunk Posture in Fowler 30°

### ABSTRAK

**Pendahuluan:** Sesak nafas pada penderita gagal jantung kongestif disebabkan oleh terganggunya fungsi paru karena adanya edema pulmonal. Salah satu upaya yang dapat dilakukan untuk mengatasi sesak nafas dan memperbaiki status oksigenasi adalah dengan mengubah posisi trunk posture in fowler 30°. **Studi kasus ini dilakukan untuk menganalisis penerapan posisi trunk posture in fowler 30° pada pasien gagal jantung kongestif yang mengalami sesak nafas. Metode:** Penelitian ini menggunakan desain evaluatif yaitu studi kasus pada pasien dengan kongestif heart failure dengan sesak nafas. **Hasil:** Setelah dilakukan observasi pemberian posisi trunk posture in fowler 30° selama 3 hari perawatan, terdapat perubahan tekanan darah, denyut nadi, pernafasan dan saturasi oksigen pasien. **Simpulan:** Posisi trunk postur in fowler 30° dapat mengurangi sesak napas pada pasien gagal jantung kongestif.

**Kata Kunci:** Gagal Jantung Kongesti, Sesak Nafas, Trunk Posture in Fowler 30°

### INTRODUCTION

Congestive heart failure (CHF) is a chronic condition in which the heart muscle is unable to pump enough blood to meet the body's need for

oxygen-rich blood. Congestive heart failure is caused by structural or functional disorders of ventricular filling or blood ejection from the heart (Yancy et al., 2017). In 2020, the Global Health

Data Exchange (GHDx) reported that the number of cases of congestive heart failure in the world reached 64.34 million cases with 9.91 million deaths (Lippi & Sanchis-Gomar, 2020). The incidence of heart failure in Indonesia was 1.5% of all patients with cardiovascular system disorders in 2018 (Kemenkes RI, 2019).

Typical signs and symptoms of patients with congestive heart failure are shortness of breath when doing activities or resting, fatigue, peripheral edema or swelling of the legs, tachycardia, tachypnea, pulmonary rales, pleural effusions, increased jugular venous pressure and hepatomegaly (Bauersachs et al., 2019). Shortness of breath (dyspnea) is the symptom most often felt by patients with congestive heart failure, which is caused by pulmonary function failure due to pulmonary edema (Rahayu, 2020). Pulmonary edema will reduce the diffusion process in the alveolar membrane, thereby interfering with gas exchange and oxygen delivery by blood to the tissues. This process will cause patients with congestive heart failure to experience a decrease in oxygen saturation and hypoxemia (Wijayati, Ningrum, & Putrono, 2019). The lying position will exacerbate shortness of breath because the fluid will be distributed to the lungs more quickly (Pambudi & Widodo, 2020).

Patients with congestive heart failure require immediate treatment, both pharmacologically and non-pharmacologically, to improve the worsening of the condition, improve the hemodynamic status, eliminate pulmonary congestion and improve tissue oxygenation (Muti, 2020). Respiratory system problems experienced by patients with congestive heart failure require prompt and appropriate treatment to prevent the worsening of the patient's condition. Nurses can perform several independent or collaborative actions to facilitate efforts to increase gas exchange and oxygen saturation in patients with congestive heart failure.

There have been many studies describing interventions that nurses can carry out independently in handling respiratory problems in patients with heart failure, including breathing exercises (mindful breathing, deep breathing

exercises), active range of motion exercises, and positioning (Pambudi & Widodo, 2020). Changing the position (positioning) of the patient is a significant action that can reduce respiratory problems. This aims to increase the volume of blood in the lungs due to the influence of gravity on venous blood flow to reduce the tightness felt by patients with congestive heart failure (Katz et al., 2018). Position selection is very influential in patients with respiratory problems. Several positions include supine, pronation, lateral, and fowler (Kozier et al., 2011).

Proper positioning is essential in heart failure patients who experience shortness of breath. One of the positions that can be done effectively to improve the hemodynamic status and oxygen saturation is the 30° trunk posture in fowler position (Kubota et al., 2015). The difference with the usual Fowler or semi-Fowler position is that besides increasing blood volume in the lungs and chest expansion, this position can reduce pressure on the abdomen and diaphragm in patients accompanied by ascites.

This position is done by elevating the straight spine parallel to the head to form a 30° angle from the bed, and then the knees are elevated to create a 15° angle. The force of gravity influences this position to help expand the chest and reduce pressure on the abdomen and diaphragm when breathing.

Based on this background, this case study-based research aimed to determine how effective the trunk posture in the fowler 30° position is in reducing shortness of breath in patients with congestive heart failure. Therefore the results of this case study can be used as an alternative position for patients with shortness of breath, especially in patients with congestive heart failure.

## METHOD

The research used a case study with data analysis using descriptive analytics in patients with congestive heart failure who experience shortness of breath. Written informed consent was obtained from the patient. The researcher obtained a research permit from the hospital with approved reference number 800/109/RSU/III/2021.

### Patient Information

The study was conducted in 2021. Patient Mr T, a 57-year-old, was treated with a medical diagnosis of class III congestive heart failure and experienced shortness of breath. The patient came to the hospital complaining of swelling all over the body since one month ago, shortness of breath, and cough. The patient has been a heavily active smoker for 21 years and has had a history of hypertension and diabetes mellitus since three years ago.

### Clinical Findings

Based on the assessment results, patients complained of shortness of breath which was felt continuously and got worse when the patient lay down or moved. The patient's consciousness is compos mentis. The patient looks weak and breathless. The results of measuring vital signs in the form of blood pressure 190/120 mmHg, respiratory rate 25x/minute with oxygen therapy 4 liters/minute using a nasal cannula, pulse 68x/minute, and temperature 36.5°C. Examination of the respiratory system revealed that the patient had grade III shortness of breath. There is chest muscle retraction with symmetrical left and right chest movements. There was no tenderness in the chest area, the results of resonant left and right lung percussion, dullness in the right basal lung, auscultation of vesicular breath sounds, and no crackles and wheezing.

The patient's conjunctiva was anemic. Percussion results found dullness on the left chest on ICS III-V and ICS III-V on the right parasternal line. At the time of auscultation at ICS II, right-left sternum, and ICS V mid-clavicle left, a regular rhythm was heard, and there were no additional sounds. CRT returns in >3 seconds, and nails appear pale and acral in both cold extremities. The patient's abdomen was ascites, and there was no tenderness, the abdomen was hard, while the liver was not assessed on palpation. Abdominal dullness percussion in the 4th quadrant with auscultation of bowel sounds 8x/minute. Both the upper and lower extremities are edematous (pitting edema ++), there is a decrease in strength in the muscles of both extremities.

The results of the supporting examination for the ECG examination revealed the presence of mitral P waves in leads I and II and inverted T in V3, V4 and V5. A chest X-ray examination revealed cardiomegaly without pulmonary engorgement and right pleural effusion. While the results of clinical chemistry and hematology examinations obtained blood sugar at 276 mg/dL, hemoglobin 10.6 g/dL, platelets 97,000/mm<sup>3</sup>, albumin 2.54 g/dL, urea 62 mg/dL, and creatinine 2 mg/dL. The therapy program given to the patient included nasal cannula oxygen 4 liters/minute, 2 ampoules of farsik/12 hours, 5 units of levemir at 22.00, novorapid 4 units (morning, afternoon, evening), omeprazole 40 mg/12 hours, vitamin K 1 ampoule/8 hours, KSR 600 mg (morning), amlodipine 5 mg/8 hours, spironolactone 1 mg (morning), candesartan 8 mg (morning), ISDN 5 mg/8 hours, concor 2.5 mg (morning), trimetazidine 1 /12 hours, aminoral 1/8 hours.

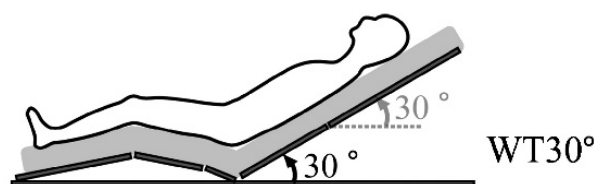


Figure 1. Position Trunk Posture in Fowler 30°  
(Kubota et al., 2017)

### Therapeutic/Nursing Intervention

The intervention given is to change the position of the trunk posture in fowler 30° in patients with congestive heart failure who experience shortness of breath. The change in position was carried out by taking into account the physical condition and comfort of the patient, the researcher changed the patient's position by elevating the bed so that the patient's position became a trunk posture in fowler 30°, where the spine is raised straight parallel to the head to form a 30° angle from the bed, then the knees are slightly elevated to form a 15° angle. Positional accuracy was measured using a simple arc ruler at the corner of the bed. This position is maintained while monitoring the patient's condition. After the first

15 minutes, the researcher will again measure the patient's vital signs to see changes in values, especially for respiratory status and oxygen saturation.

**Follow-up and Outcomes**

Measurement of blood pressure, pulse and respiration rate were measured before being given a position change intervention. After 15 minutes of intervention, measurements were taken to evaluate the changes. The intervention will be stopped if the patient feels a difference in a worse direction, such as feeling more congested and anxious.

**RESULT AND DISCUSSION**

After changing the supine position to trunk posture in fowler 30°, there was a change in the patient's blood pressure, pulse rate, respiration and oxygen saturation. The results of the evaluation obtained in the patient after changing position were the patient's awareness of *compos mentis*, no excessive use of auxiliary respiratory muscles were seen, a decrease in hemodynamic values approaching normal limits, and an increase in oxygen saturation. The patient's response to this position change was that shortness of breath was reduced, and they felt more comfortable.

**Table 1. Observation of Vital Signs after Intervention in Trunk Posture in Fowler 30°**

No	Data	Before the position of the trunk posture in fowler 30°	After the position of the trunk posture in fowler 30°
1	Blood pressure	190/100 mmHg	180/90 mmHg
2	Respiratory rate	24 x/minute	19 x/minute
3	Pulse rate	75-76 x/minute	73-75 x/minute
4	Oxygen saturation	95%	97-99%.

Based on the table above, after being given the position change intervention, there was a decrease in blood pressure from 190/100 mmHg to 180/90 mmHg. There is a decrease in the respiratory rate to within normal limits and an increase in oxygen saturation. From these results, nursing problems can be partially resolved, where the patient's response to the intervention can overcome the symptoms that arise in patients with congestive heart failure, namely shortness of breath. Shortness of breath felt by the patient decreased, and oxygen saturation increased after being given a trunk posture in the fowler 30° position.

Choosing the right position can relieve shortness of breath experienced by patients with congestive heart failure, one of which is the Fowler's position. Fowler's position or semi-sitting position is a position that is often applied clinically in providing comfort to the patient. This position is given by tilting the bed back up between 30° and 60° from the supine position with the knees out or straight (Kubota et al., 2015). Previous studies tested whether stroke volume (SV) was higher and heart rate (HR) lower in Fowler's position with the

upper body upright than in Fowler's position with the whole body upright in older and younger subjects. The results showed that the upright scion during Fowler's position enabled maintenance of SV and inhibited tachycardia response compared to the upright trunk, regardless of age. An upright scion in Fowler's position can help reduce orthostatic stress and facilitate routine activities and conversation in debilitated patients (Kubota et al., 2017).

The Fowler position used in this case study is a trunk posture in the fowler 30° position, performed by elevating the straight spine parallel to the head to form an angle of 30° from the bed. The knees are slightly elevated to create a 15° angle. The trunk posture in the fowler 30° position can reduce shortness of breath by helping to increase maximum lung expansion. Oxygen consumption of heart failure patients with this position can also be reduced compared to the lying position, where the position of the organs in the abdomen that compresses the diaphragm is minimal. Congestive heart failure patients positioned in a trunk posture in fowler 30o can reduce venous return to the atria, thereby reducing

end-diastolic volume and improving ventricular function. The lower extremities in this position support the force of gravity to facilitate blood flow to the periphery. The trunk posture in the fowler 30° position supports congestive heart failure patients to rest to reduce the burden on the heart and maintain a stable stroke volume. The reduced heart load and stable stroke volume support the pulse rate and blood pressure to reach normal limits (Kubota et al., 2015; Awolola et al., 2022).

With the provision of a trunk posture in the fowler 30° position, there is a change in blood pressure, pulse, respiration, and saturation status toward normal. This intervention is also relatively easy to perform with minimal equipment preparation. It is necessary to measure hemodynamic and respiratory status changes regularly to get accurate intervention results.

## CONCLUSION

This research revealed that applying a trunk posture in fowler 30° can reduce shortness of breath in patients with congestive heart failure by helping to increase maximal lung expansion, lower oxygen consumption, and minimize diaphragmatic compression. The trunk posture in the fowler 30° position can also reduce the burden on the heart and maintain a stable stroke volume, thereby helping to achieve normal blood pressure and pulse rate. Providing a trunk posture in the fowler 30° position can be used as an intervention option to support pharmacological therapy in patients with congestive heart failure with complaints of shortness of breath.

## REFERENCES

- Awolola, E. O., Maharaj, S. S., Ojo, O. T., & Adeyeye, O. O. (2022). Efficacy of Pulmonary exercise administered in Supine, 45 degrees, or 90 degrees long sitting position on pulmonary parameters of patients with COPD: A Study Protocol. *medRxiv*. <https://doi.org/10.1101/2022.01.30.22270106>
- Bauersachs, J., König, T., van der Meer, P., Petrie, M. C., Hilfiker-Kleiner, D., Mbakwem, A., . . . de Boer, R. A. (2019). Pathophysiology, diagnosis and management of peripartum cardiomyopathy: a position statement from the Heart Failure Association of the European Society of Cardiology Study Group on peripartum cardiomyopathy. *European journal of heart failure*, 21(7), 827-843. <https://doi.org/10.1002/ejhf.1493>
- Katz, S., Arish, N., Rokach, A., Zaltzman, Y., & Marcus, E.-L. (2018). The effect of body position on pulmonary function: a systematic review. *BMC pulmonary medicine*, 18(1), 1-16. <https://doi.org/10.1186/s12890-018-0723-4>
- Kemenkes RI. (2019). *Laporan Nasional Rischesdas 2018*. Jakarta: Lembaga Penerbit Badan Penelitian dan Pengembangan Kesehatan (LPB).
- Kozier, B., Erb, G., Berman, A., & Snyder. (2011). *Buku Ajar Fundamental Keperawatan, Konsep, Proses dan Praktik* (7 ed. Vol. 1). Jakarta: EGC.
- Kubota, S., Endo, Y., Kubota, M., Ishizuka, Y., & Furudate, T. (2015). Effects of trunk posture in Fowler's position on hemodynamics. *Autonomic Neuroscience*, 189, 56-59. <https://doi.org/10.1016/j.autneu.2015.01.002>
- Kubota, S., Endo, Y., Kubota, M., & Shigemasa, T. (2017). Assessment of effects of differences in trunk posture during Fowler's position on hemodynamics and cardiovascular regulation in older and younger subjects. *Clinical interventions in aging*, 12, 603. <https://doi.org/10.2147%2FCIA.S132399>
- Kupper, N., Bonhof, C., Westerhuis, B., Widdershoven, J., & Denollet, J. (2016). Determinants of Dyspnea in Chronic Heart Failure. *Journal of Cardiac Failure*, 22(3), 201–209. <https://doi.org/10.1016/j.cardfail.2015.09.016>
- Lippi, G., & Sanchis-Gomar, F. (2020). Global epidemiology and future trends of heart failure. *AME Med J*, 5(15), 1-6. <https://doi.org/10.21037/amj.2020.03.03>
- Muti, R. T. (2020). Pengaruh Posisi Semi Fowler Dengan Kombinasi Lateral Kanan Terhadap Perubahan Haemodinamik Pada Pasien

- Gagal Jantung Di Ruang ICCU Rumah Sakit Umum Daerah Margono Soekarjo Purwokerto. *Viva Medika: Jurnal Kesehatan, Kebidanan Dan Keperawatan*, 13(02), 124-140. <https://doi.org/10.35960/vm.v13i02.519>
- Najafi, S., Dehkordi, S. M., Haddam, M. B., Abdavi, M., & Memarbashi, M. (2018). The effect of position change on arterial oxygen saturation in cardiac and respiratory patients: A randomized clinical trial. *Journal of Clinical and Diagnostic Research*, 12(9), OC33–OC37. <https://doi.org/10.7860/JCDR/2018/36282.12130>
- Pambudi, D. A., & Widodo, S. (2020). Posisi Fowler Untuk Meningkatkan Saturasi Oksigen Pada Pasien (CHF) Congestive Heart Failure Yang Mengalami Sesak Nafas. *Ners Muda*, 1(3), 146-151. <https://doi.org/10.26714/nm.v1i3.5775>
- Puspita, D., Nur, B. M., & Jumaiyah, W. (2019). Efektifitas Posisi Tidur Miring Kanan dan Semifowler Terhadap Kualitas Tidur Pada Pasien Gagal Jantung Kongestif Di RSUD Dr. Soedarso Pontianak. *Jurnal Keperawatan Dan Kesehatan*. Retrieved from <http://jurnal-stikmuh-ptk.id/index.php/JK2/article/view/105>
- Rahayu, L. P. (2020). Management Pengoptimalan Kebutuhan Oksigen Pada Pasien Gagal Jantung Di Unit Perawatan Intensif: A Literatur Review. *Jurnal Berita Ilmu Keperawatan*, 13(2), 84-92. <https://doi.org/10.23917/bik.v13i2.11499>
- Virani, S. S., Alonso, A., Aparicio, H. J., Benjamin, E. J., Bittencourt, M. S., Callaway, C. W., Tsao, C. W. (2021). Heart Disease and Stroke Statistics-2021 Update: A Report From the American Heart Association. In *Circulation* (Vol. 143). <https://doi.org/10.1161/CIR.0000000000000950>
- Wijayati, S., Ningrum, D. H., & Putrono, P. (2019). Pengaruh Posisi Tidur Semi Fowler 450 Terhadap Kenaikan Nilai Saturasi Oksigen Pada Pasien Gagal Jantung Kongestif Di RSUD Loekmono Hadi Kudus. *Medica Hospitalia: Journal of Clinical Medicine*, 6(1), 13-19. <https://doi.org/10.36408/mhjcm.v6i1.372>
- Yancy, C. W., Jessup, M., Bozkurt, B., Butler, J., Casey Jr, D. E., Colvin, M. M., . . . Givertz, M. M. (2017). 2017 ACC/AHA/HFSA focused update of the 2013 ACCF/AHA guideline for the management of heart failure: a report of the American College of Cardiology/American Heart Association Task Force on Clinical Practice Guidelines and the Heart Failure Society of America. *Journal of the American College of Cardiology*, 70(6), 776-803. <http://dx.doi.org/10.1016/j.jacc.2017.04.025>